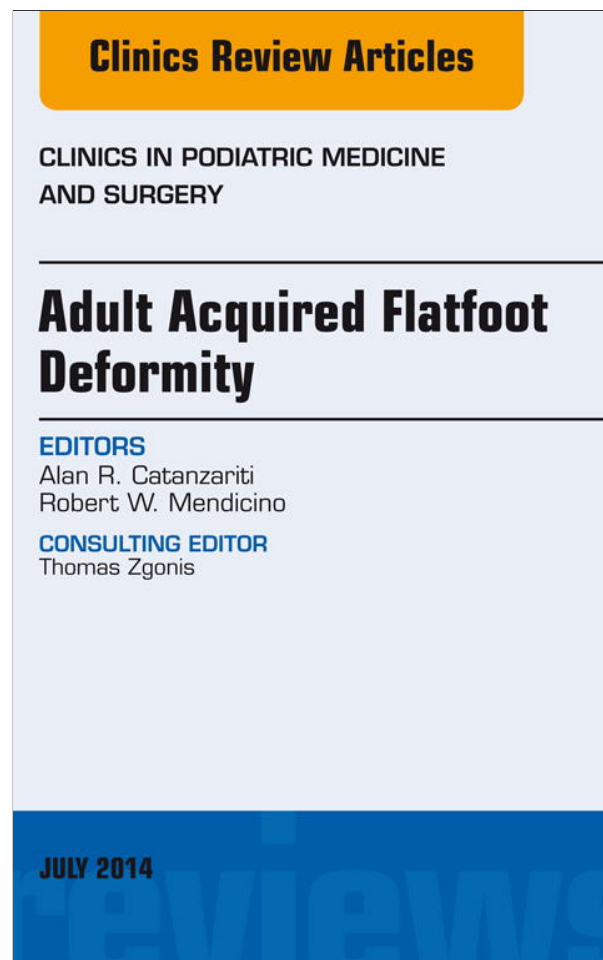

This article appeared in a journal published by Elsevier. The attached copy is furnished to the author for internal non-commercial research and education use, including for instruction at the authors institution and sharing with colleagues.

Other uses, including reproduction and distribution, or selling or licensing copies, or posting to personal, institutional or third party websites are prohibited.

In most cases authors are permitted to post their version of the article (e.g. in Word or Tex form) to their personal website or institutional repository. Authors requiring further information regarding Elsevier's archiving and manuscript policies are encouraged to visit:

<http://www.elsevier.com/authorsrights>



# Addressing Stage II Posterior Tibial Tendon Dysfunction

## Biomechanically Repairing the Osseous Structures Without the Need of Performing the Flexor Digitorum Longus Transfer

Lawrence A. DiDomenico, DPM<sup>a,b,c,\*</sup>, Zachary M. Thomas, DPM<sup>c</sup>,  
Ramy Fahim, DPM, AACFAS<sup>a</sup>

### KEYWORDS

- Posterior tibial tendon dysfunction • Adult acquired flatfoot deformity
- Flexor digitorum longus • Calcaneal slide osteotomy

### KEY POINTS

- A double calcaneal osteotomy, a gastrocnemius recession and stabilization of the medial column provides satisfactory correction, stability, and realignment of the foot.
- The use of the flexor digitorum longus transfer, can be avoided without compromising the outcome when surgically treating posterior tibial tendon dysfunction.

### INTRODUCTION

Adult acquired flatfoot deformity is characterized by collapse of the medial longitudinal arch and loss of the mechanical advantage of the posterior-medial soft-tissue structures, including the posterior tibial tendon. Key<sup>1</sup> initially described a chronic partial rupture of the posterior tibial tendon in 1953.

Further literature confirmed an association with this abnormality and, in fact, “dysfunction” of this posterior tibial tendon with adult acquired flatfoot deformity. The clinical presentation of adult flatfoot can range from a flexible deformity with normal joint integrity to a rigid, arthritic flat foot. Conservative and surgical management of flatfoot deformity has been reviewed extensively in the literature, but debate still exists regarding the surgical management of stage II deformities, especially in the presence of medial column instability. Historically triple arthrodesis was a common surgical approach; however, the increased incidence and awareness of posterior tibial

---

<sup>a</sup> Ankle & Foot Care Centers, 8175 Market Street, Youngstown, OH 44512, USA; <sup>b</sup> St. Elizabeth Hospital, Youngstown, Ohio; <sup>c</sup> Heritage Valley Hospital, Beaver, Pennsylvania, USA

\* Corresponding author.

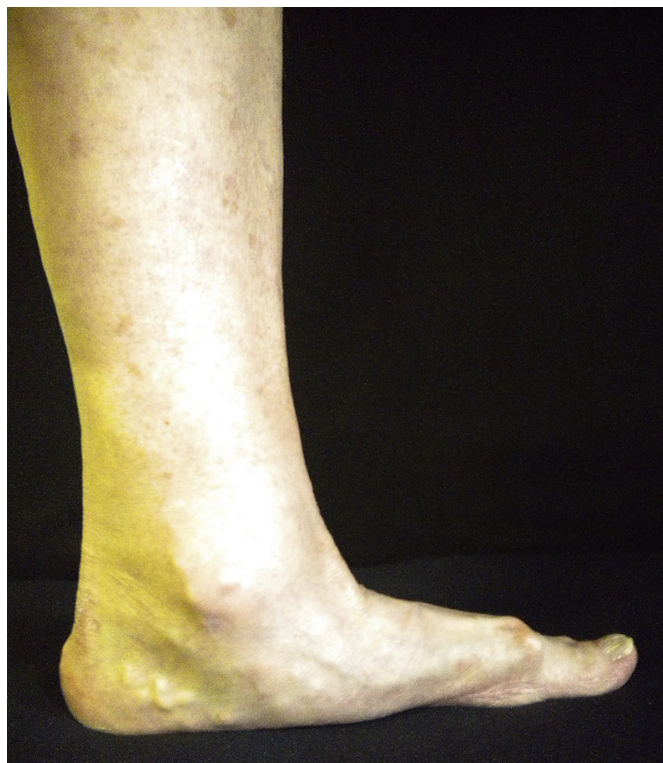E-mail address: [ld5353@aol.com](mailto:ld5353@aol.com)

tendon dysfunction has stimulated a trend toward surgical interventions that involve joint preservation techniques.<sup>2,3</sup>

The purpose of this article is to review and discuss various surgical options for the correction of stage II flatfoot reconstructive procedures. The authors discuss their opinion that is not always necessary to transfer the flexor digitorum longus tendon to provide relief and stability in this patient population. The article focuses on the anatomy, diagnosis, and current treatments of flexible flatfoot deformity (**Fig. 1**).

### FUNCTIONAL ANATOMY

The tibialis posterior arises from the posterior aspect of the tibia and is part of the deep posterior compartment. The tendon divides in the proximity to the navicular tuberosity into 3 slips: the anterior, middle, and posterior. The anterior slip is the largest of these, and also is the slip considered to be the continuation of the posterior tibial tendon proper. This slip inserts on to the navicular tuberosity, first cuneiform-navicular joint, and inferior first cuneiform. The middle tendon slip fans out like multiple tentacles that travel deep into the plantar vault of the foot inserting on the second and third cuneiform, lateral second metatarsal base, medial and lateral third metatarsal base, medial fourth metatarsal base, and cuboid. Occasionally there is a slip to the fifth metatarsal base. At the level of the midfoot this portion of tendon gives origin to the flexor hallucis brevis. The tendon also crosses deep to the peroneus longus and, in some instances, directly interacts with this tendon by tendinous attachment. The posterior component of the tibialis posterior travels lateral and posterior to insert on the sustentaculum tali.<sup>4</sup> Ultrasonographic imaging of the tibialis posterior shows a mean width of 9.72 to 11.12 mm, thickness of 3.42 to 3.64 mm, and cross-sectional area of 2.66 to 3.07 mm<sup>2</sup> based on 3 observers. Magnetic resonance imaging (MRI) shows measurements of 10.65 to 11.11 mm width, thickness of 3.95 to 4.18 mm, and cross-sectional area of 3.17 to 4.06 mm<sup>2</sup>.<sup>5</sup>



**Fig. 1.** Medial aspect of the left foot of a patient who suffers from stage II posterior tibial tendon dysfunction.

The flexor digitorum longus originates from the posterior tibia and interosseous membrane. The tendon courses under the sustentaculum tali as part of the deep posterior compartment. The tendon of the flexor digitorum longus traverses plantar to the flexor hallucis longus and travels anteriorly and laterally before it splits in to 4 slips, each inserting on their respective lesser digital distal phalanx. The tendon of the flexor digitorum longus also gives origin to the quadratus plantae.<sup>4</sup> Ultrasonographic measurements of the flexor digitorum longus show a mean cross-sectional area of 1.59 to 176 mm<sup>2</sup>.<sup>6</sup>

The course of the posterior tibial tendon runs slightly superior to the flexor digitorum longus. The flexor digitorum longus runs in a more axial fashion than the posterior tibial tendon. The higher angle of descent of the posterior tibial tendon places it in the ideal location for its strap-like, arch-supporting function.

When transferring the flexor digitorum longus to the posterior tibial tendon insertion, the flexor digitorum longus cannot recreate the trajectory of the posterior tibial tendon. Moreover, when transferring the flexor digitorum longus into the navicular or medial cuneiform, the tentacle-like insertions of the posterior tibial tendon are sacrificed.

In addition the spring ligament, the deltoid ligament complex, and the articular relationship of the talonavicular and subtalar joints can be affected in the presence of posterior tibial tendon dysfunction.

The vascularity of the posterior tibial tendon originates from branches of the posterior tibial artery. Superior to the medial malleolus, the posterior tibial tendon has vessels in the synovial sheath, which come from muscle tissue. Distally the insertion receives its blood supply from the periosteal tissue. In between is a zone of hypovascularity, which often corresponds to the site of the diseased tendon.<sup>7</sup>

## **PATHOLOGY**

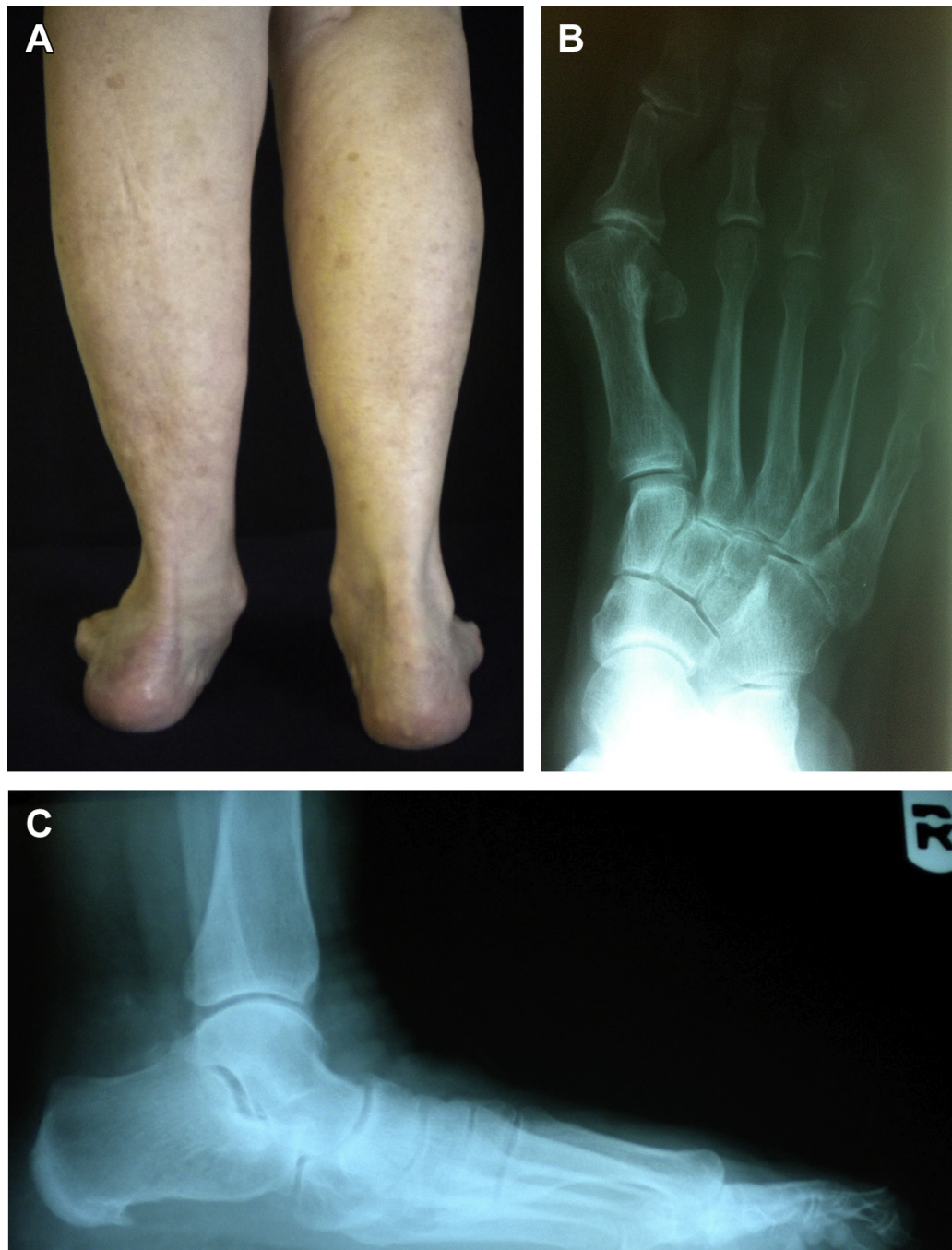Biomechanical imbalance can lead to chronic microtrauma in the posterior tibial tendon. In addition, advanced age lessens tendon elasticity because of changes in collagen structure that create tendon weakness.<sup>8</sup> Poor blood supply may stimulate this disease process and may preclude healing of the tendon, leading to a chronic inflammatory state that creates tenosynovitis and tendinosis. Deland and colleagues<sup>9</sup> demonstrated that medial calcaneonavicular ligaments and the interosseous ligament are often implicated in posterior tibial tendon dysfunction. Other causes include medical conditions such as ligamentous laxity and trauma to the posterior tibial tendon. More common are biomechanical conditions associated with posterior tibial dysfunction. This patient population typically presents with an equinus contracture, a medial column instability that can lead to a forefoot varus and a hindfoot valgus.

## **CLASSIFICATION**

Johnson and Strom<sup>10</sup> described 3 stages of posterior tibial tendon dysfunction, with Myerson and Bluman<sup>11</sup> describing a fourth stage.

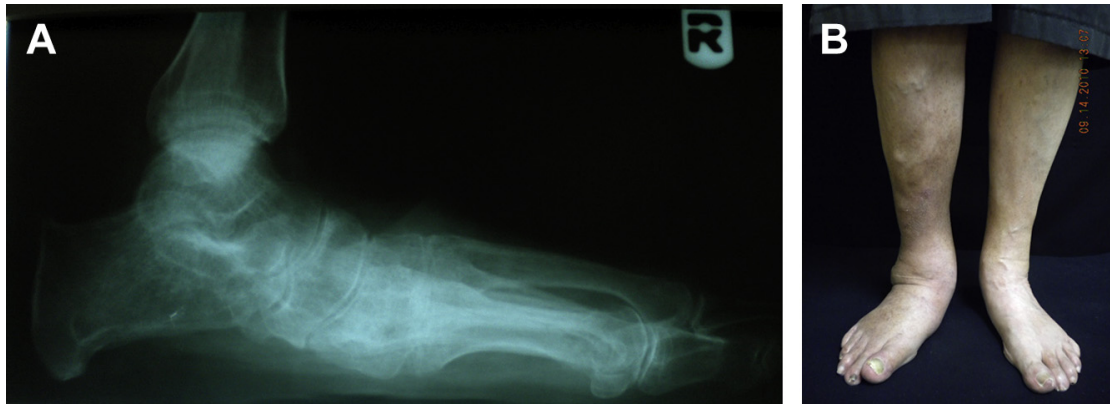Stage I is described as painful tenosynovitis of the posterior tibial tendon. The patient is able to perform a single-limb heel rise. The hindfoot is supple. In this stage, a period of immobilization in a walking cast or walking boot followed by either ankle-foot orthosis or an orthotic can often manage this condition successfully.

Stage II is characterized by an elongated posterior tibial tendon, medial pain, and a mobile hindfoot valgus that corrects to neutral on heel rise. A single-limb heel-rise test shows marked weakness. There is a positive “too many toes” sign. Stage II can also be subdivided into IIA (<30% uncovering of talar head), IIB (>30% uncovering of talar head), and IIC, which is stage II posterior tibial tendon dysfunction with associated forefoot varus (**Fig. 2**).



**Fig. 2.** (A) A patient diagnosed with stage II posterior tibial tendon dysfunction. Note the “too many toes” sign, calcaneal valgus malalignment, posterior-medial bulge, and forefoot abduction of the left foot. (B) Anteroposterior (AP) radiograph of a patient who suffers from posterior tibial tendon dysfunction. Note the malalignment and malrotation of the midtarsal joint. (C) Lateral radiograph showing the malalignment of the hindfoot and mid-foot. Note the elevated first metatarsal demonstrating instability of first tarsometatarsal.

Stage III is rigid hindfoot valgus that does not correct on double-limb heel rise. The patient may not be able to perform a double-limb heel rise, and is unable to perform a single-limb heel rise. There is a positive “too many toes” sign. There may be significant rearfoot arthritis. Pain is noted medially, and also can be lateral, owing to impingement of lateral talar process.<sup>10</sup> Extra-articular osteotomies may be attempted to treat this stage; however, serious consideration should be given to fusion of the talonavicular and/or subtalar joint (**Fig. 3**).



**Fig. 3.** (A) Lateral radiograph showing significant hindfoot and midfoot arthrosis. (B) Clinical view of a patient who experiences stage III posterior tibial dysfunction on the right side.

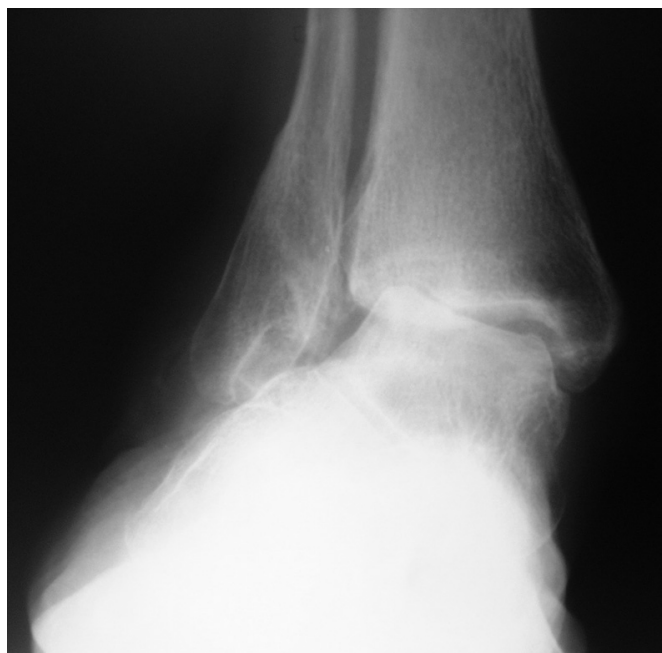Stage IV deformities are a progression of stage III, with associated tibiotalar valgus and possible arthrosis as a result of the prolonged hindfoot valgus.<sup>11</sup> The treatment of stage IV pes planovalgus is the same as for stage III; however, pain in the ankle joint must also be addressed by means of cautious monitoring, cartilage repair, fusion, or total ankle arthroplasty (**Fig. 4**).

It should be noted that this classification system is mentioned to provide an organized and categorized system to define the stages of the deformity. Clinicians must realize that there can be much overlap of findings from one stage to another, and there exists a spectrum of underlying abnormalities between these stages.

Other classification systems that describe the disorders associated with the dysfunction of the posterior tibial tendon also exist, but are beyond the scope of this article. The reader is encouraged to consult the corresponding references for more detail.<sup>12,13</sup>

### OPERATIVE MANAGEMENT

For the purposes of this review, the authors focus here on the operative management of stage II deformities. The adult flexible flatfoot deformity is often the direct result of



**Fig. 4.** AP view of ankle showing medial deltoid insufficiency with a posterior tibial tendon dysfunction, stage IV.

dysfunction of the posterior tibial tendon, and eventually the deformity leads to changes in the soft tissues of the medial longitudinal arch. Past surgical approaches included midfoot and hindfoot arthrodesis, and more recent literature suggests the transfer of the flexor digitorum longus tendon combined with a medial calcaneal osteotomy. In addition, some investigators are suggesting the use of a subtalar arthroereisis implant as a potential alternative for the correction of hindfoot valgus.

#### ***Isolated Flexor Digitorum Longus Transfer to Navicular***

---

Although this procedure has been described in the past, without correction of the structural abnormalities in the hindfoot, any pure soft-tissue procedure cannot withstand the long-term valgus stress placed on the foot.<sup>12,14–16</sup>

#### ***Medial Calcaneal Slide Osteotomy and Posterior Tibial Tendon Augmentation***

---

The osteotomy is commonly done to protect the tendon transfer by improving the supinatory capacity of the gastrocsoleus complex.<sup>17</sup> Brodsky<sup>18</sup> noted significant improvements in the postoperative gait analysis for patients undergoing medial calcaneal osteotomies in conjunction with flexor digitorum longus transfer to the navicular tuberosity. He specifically noted improvements in cadence, stride length, and ankle push-off. Furthermore, studies by Myerson,<sup>19</sup> Fayzi and colleagues,<sup>20</sup> Wacker and colleagues,<sup>21</sup> Guyton and colleagues,<sup>22</sup> and Sammarco and Hockenbury<sup>23</sup> demonstrated a high rate of successful results with short to intermediate follow-up. These studies were mostly level IV case series, but nonetheless demonstrated predictably good outcomes.

These studies do not explain the extent to which the flexor digitorum longus transfer is involved in maintaining longitudinal arch correction, specifically on a long-term basis. There is no way to determine whether the calcaneal slide osteotomy, which offloads the medial column and creates a medializing pull of the Achilles tendon, causes the pain reduction or if the transferred tendon contributes to a reduction in pain.

#### ***Lateral Column Lengthening and Posterior Tibial Tendon Augmentation***

---

This procedure was originally described in the pediatric population, using a tricortical graft.<sup>24</sup> Correction of the deformity is accomplished by adducting and plantarflexing the midfoot around the talar head. Hinterman and colleagues<sup>25</sup> and Toolan and colleagues<sup>26</sup> reported promising results in their case series. However, complications of forefoot varus, lateral column overload, nonunion, and graft failure have been reported in other level IV studies.

#### ***Double Calcaneal Osteotomies and Posterior Tibial Tendon Augmentation***

---

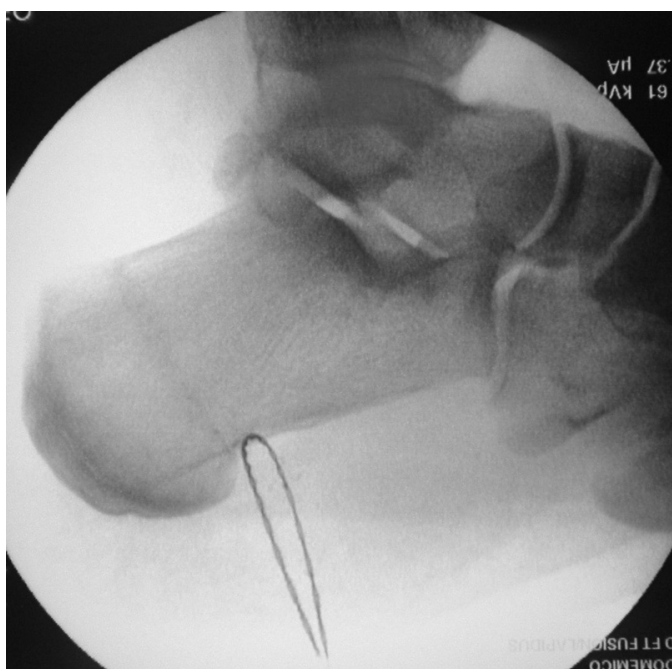
The combination of the Evans calcaneal osteotomy and the medializing calcaneal slide osteotomy provides a powerful correction and further decreases the load on the posterior-medial structures in comparison with a single osteotomy. In doing so, there is also improvement in overall alignment of the forefoot and midfoot in relation to the hindfoot. Moseir-LaClair and colleagues<sup>27</sup> demonstrated this point in their case series. However, no direct conclusion was drawn regarding the individual benefit of the flexor digitorum longus transfer in this procedure. When this is combined with a posterior group lengthening it has been named The “All American” procedure, as described by Manoli and Pomeroy.<sup>28</sup> The surgical correction includes lateral column lengthening, medializing calcaneal slide osteotomy, flexor digitorum longus transfer to the navicular, and posterior group lengthening.

## SURGICAL APPROACH AND EXPERIENCE

In patients who do not demonstrate a significant tear, it has been the experience of the authors to not perform a flexor digitorum longus tendon transfer in those who suffer from stage II posterior tibial tendon dysfunction. The choice of procedures focuses on mechanically realignment of the pathologic foot. The postoperative immobilization with the foot and ankle in a corrective position appears to treat the posterior tibial tendon disorder adequately without the need for an invasive procedure. Postoperatively the foot and ankle are cast and mechanically maintained in the corrected position. This action removes the abnormal stresses placed on the posterior tibial tendon, and provides an environment for the posterior tibial tendon to remodel in a biomechanically corrected position. It has been the authors' experience that the mechanically corrected foot and ankle now protects the rested and "healed" posterior tendon, and prevents future fatigue and disease in the posterior tendon.

Patients are placed in a supine position on the operating table with general anesthesia administered. An ipsilateral pneumatic thigh tourniquet is used to provide hemostasis. A repeat Silfverskiöld test is performed intraoperatively to confirm clinical testing.<sup>29</sup> In the authors' experience, most patients have presented with isolated gastrocnemius equinus when presenting with a symptomatic posterior tibial tendon dysfunction. The posterior muscle group contracture is addressed by either a gastrocnemius recession (endoscopic or open) in the presence of a gastrocnemius equinus, or a tendoachilles lengthening in the presence of a gastrocsoleus equinus. Extra-articular osteotomies of the hindfoot are then executed via a medializing percutaneous calcaneal displacement osteotomy.<sup>30</sup> A Gigli saw is used to execute the osteotomy using a sequence of 4 stab incisions. Following subperiosteal dissection, the Gigli saw is placed in the desired position and the position confirmed fluoroscopically. The Gigli saw should be in position to exit distal to the calcaneal tuberosity (Fig. 5).

The osteotomy is executed, taking care not to violate the plantar soft-tissues structure on the plantar cortical exit. The saw is cut at the skin edge and removed. The osteotomy is then placed in the corrected medialized position. Next, 2 parallel guide wires are placed perpendicular to the osteotomy site in preparation for insertion of



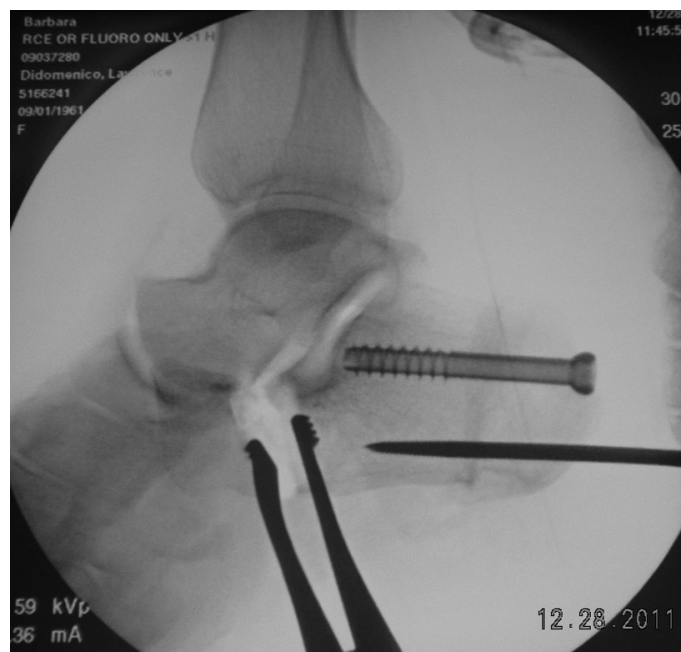
**Fig. 5.** Intraoperative fluoroscopy showing a percutaneous calcaneal displacement osteotomy.



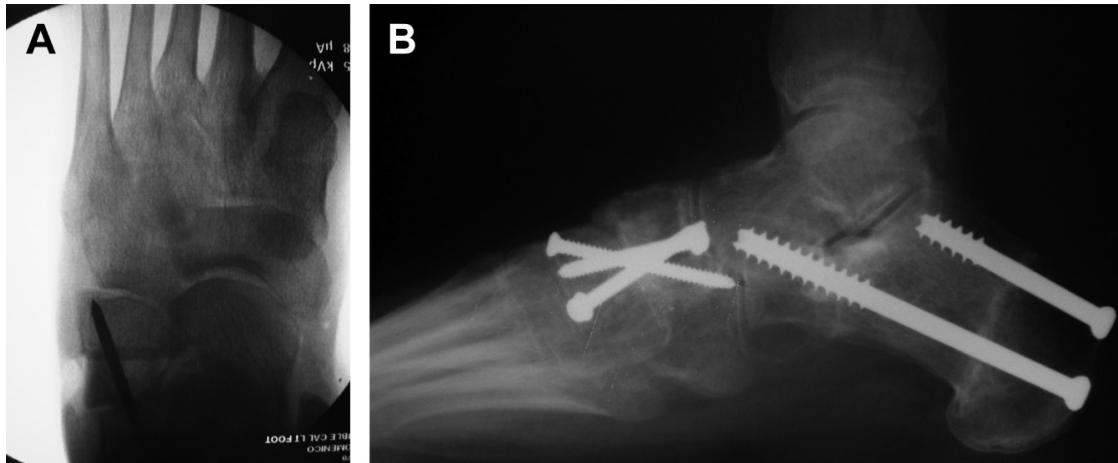
2 large, partially cancellous screws. Subsequently, the midtarsal joint is evaluated for instability with abduction. If there is no instability, the perpendicular calcaneal osteotomy is fixated with 2 large cancellous screws. If instability is present, an Evans calcaneal osteotomy is performed through an oblique lateral incision, taking care to protect the sural nerve and peroneal tendons. The lengthening is performed with the use of a tricortical allograft. The fixation of choice is large, long, partially threaded cancellous screws. At this point the percutaneous calcaneal osteotomy is fixated first (**Fig. 6**). The first screw inserted is the most superior screw. Insertion is accomplished with typically a short, large, partially threaded cancellous screw, ensuring that the threaded portion of the screw is distal to the osteotomy, resulting in interfragmentary compression of the osteotomy. Next, the authors use a dual-function technique for which the inferior screw is a long, partially threaded cancellous screw.<sup>31</sup> This screw is used to compress the inferior aspect of the percutaneous calcaneal osteotomy and also serves as a positional screw in the distal segment of the Evans calcaneal osteotomy. The purpose of this maneuver is to maintain the length of the Evans osteotomy while providing interfragmentary compression to the percutaneous calcaneal osteotomy site. This technique provides a significant amount of correction, with minimal dissection to the soft tissues and the use of intramedullary fixation. The use of intrafragmentary fixation preserves the soft-tissue structures and prevents the potential complications of painful palpable hardware on the lateral aspect of the calcaneus, and negates the need for soft-tissue stripping if one fixates the Evans osteotomy with a laterally based plate (**Fig. 7**).

If necessary, the medial column is then addressed. In cases where a forefoot varus, osteoarthritis, or instability/hypermobility is identified, the surgeon must recognize which joint or joints of the medial column are involved. The abnormality is corrected by stabilizing the affected joints with an arthrodesis. The goal of the arthrodesis is to adduct and plantarflex the abducted foot into an anatomic position, creating a plantigrade foot, and to reestablish the tripod effect (**Fig. 8**).

The posterior muscle lengthening, a single or double calcaneal osteotomy, and the medial column fusion allow the surgeon to preserve the essential joints. This technique



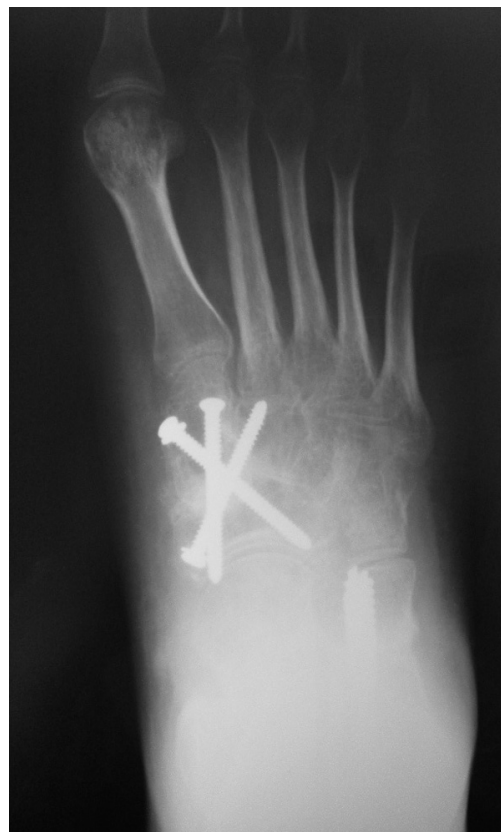**Fig. 6.** Lateral intraoperative projection showing fixation of the percutaneous calcaneal osteotomy with interfragmentary compression (superior screw). A guide wire is inserted in preparation for insertion of a dual-function screw across the Evans calcaneal osteotomy.



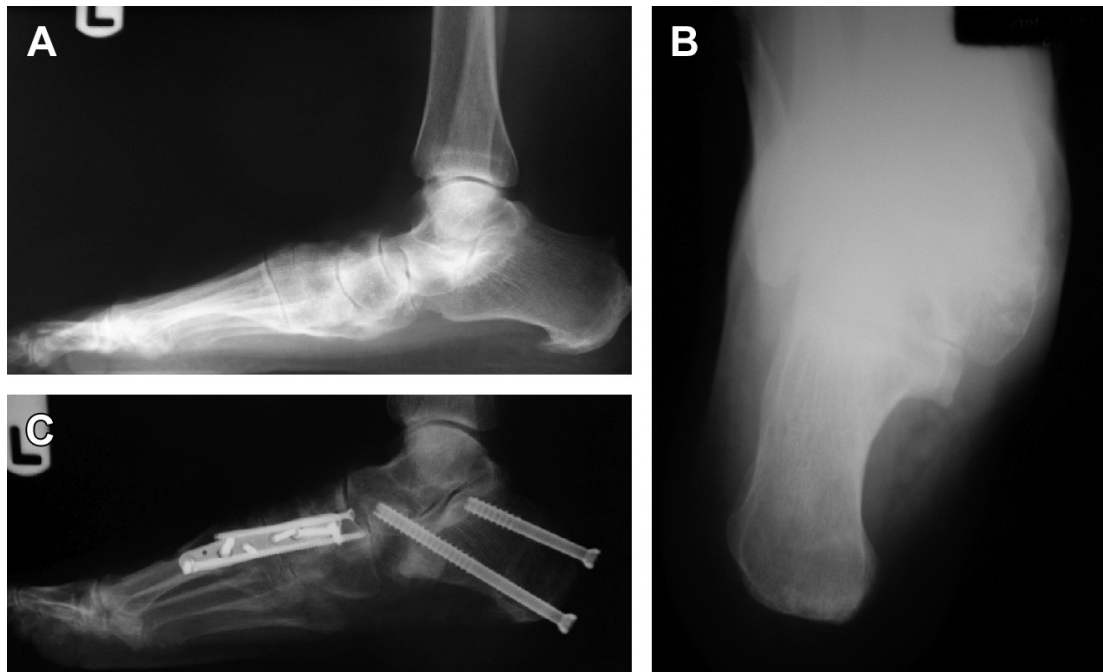
**Fig. 7.** (A) An anterior to posterior guide wire inserted in preparation for a dual-function screw. Note the intramedullary fixation of the Evans calcaneal osteotomy. (B) Postoperative lateral radiograph showing the dual-function screw. This screw serves as a positional screw around the Evans osteotomy and an interfragmentary compression screw at the site of the percutaneous calcaneal osteotomy.

provides a stable plantigrade foot and places the foot into anatomic alignment, providing mechanical advantage and eliminating the abnormal stress to the posterior tibial tendon (**Figs. 9** and **10**).

Postoperative care consists of a compressive postoperative bandage and a uni-valve postoperative cast with an anterior evacuation.<sup>32</sup> At 2 weeks the plaster cast is exchanged for a below-the-knee fiberglass cast, which is worn for approximately 4 more weeks as determined by postoperative radiographs. The patient is then



**Fig. 8.** Postoperative AP radiograph showing a navicular-cuneiform arthrodesis to stabilize the medial column.



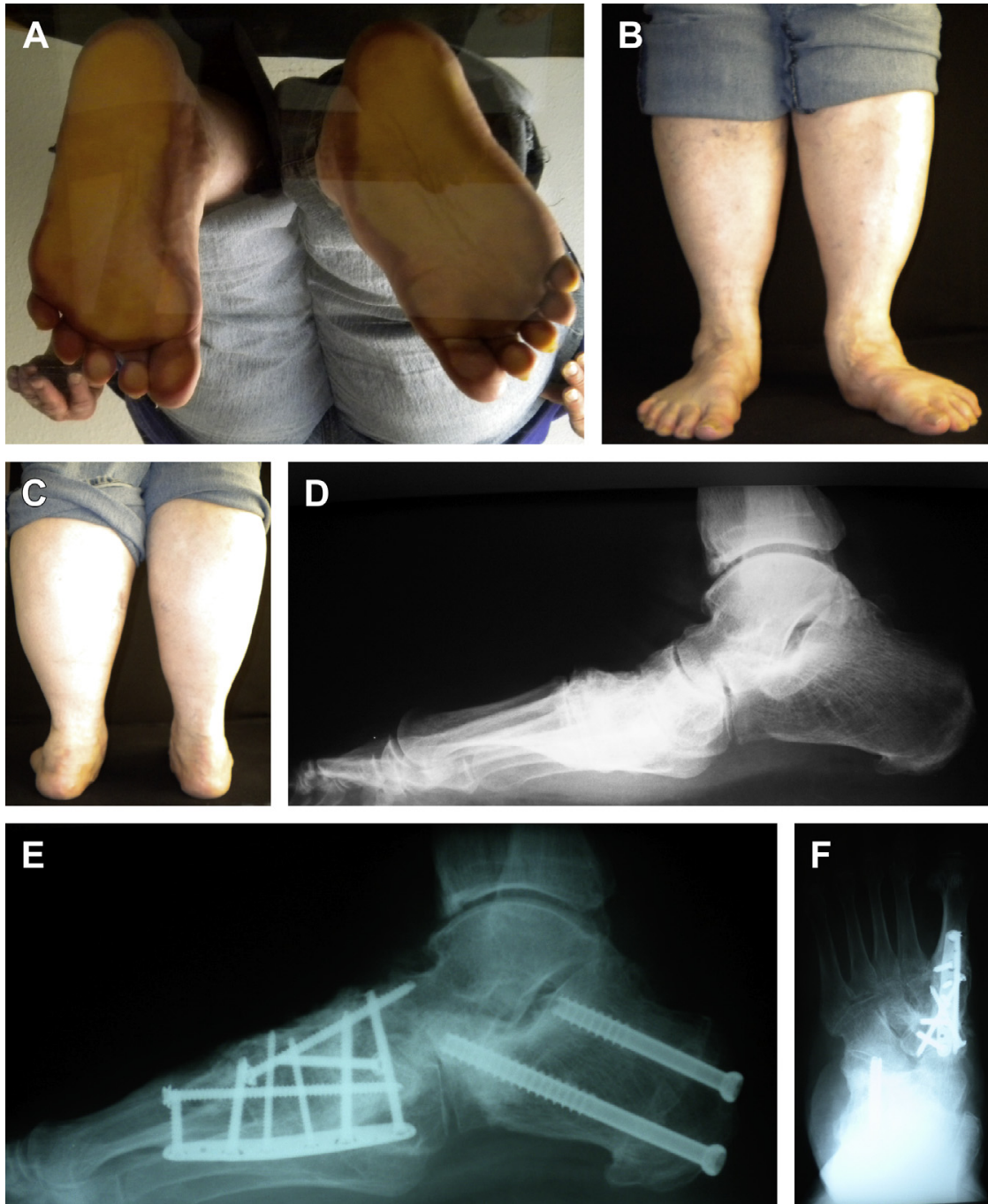
**Fig. 9.** (A) Preoperative lateral projection showing malalignment of midfoot and hindfoot causing abnormal forces along the posterior tibial dysfunction. (B) Preoperative view of hindfoot alignment showing a calcaneal valgus, resulting in abnormal forces that lead to a posterior tibial tendon dysfunction. (C) Postoperative lateral radiograph showing the foot of a patient who underwent an endoscopic gastrocnemius recession, a percutaneous calcaneal displacement osteotomy, an Evans calcaneal osteotomy, and a midfoot fusion. Note the realignment of the midfoot and hindfoot, therefore decreasing the stress to the posterior tibial tendon. Surgery was not performed on the posterior tibial tendon, and the biomechanically realigned foot provides adequate support to the posterior tibial tendon without the need of a flexor digitorum longus transfer.

transitioned to a controlled ankle motion boot (CAM), and physical therapy is instituted. The patient is then transitioned to regular shoe gear as tolerated.

#### ***Lack of Flexor Digitorum Longus Transfer***

In the authors' previous case series of 34 patients, considerable radiographic correction was accomplished in performing extra-articular hindfoot osteotomies as well as medial column fusions. Without performing a flexor digitorum longus tendon transfer, patients demonstrated successful postoperative outcomes over an average follow-up period of 14 months.<sup>33</sup>

Many surgeons augment the repair with a flexor digitorum longus tendon transfer to restore and attempt to recreate the function of the posterior tibial tendon. Some surgeons follow a school of thought advising to resect the "diseased" posterior tibial tendon to remove degenerative tissue. Valderrabano and colleagues<sup>34</sup> suggest that this may not always be necessary. These investigators performed MRI analysis of the posterior tibial tendon in patients who underwent flatfoot reconstruction. The study revealed although fatty degeneration of the posterior tibial muscle was present in all patients preoperatively, there was a decrease in degeneration with increasing strength of the posterior tibial muscle and muscular size postoperatively. In addition, they established that the recovery potential of the posterior tibial muscle was significant even after delayed repair of a diseased tendon. Valderrabano and colleagues<sup>34</sup> suggested that the posterior tibial tendon should not be transected because it precludes the recovery potential of the posterior tibial muscle.



**Fig. 10.** (A) This patient suffers from posterior tibial tendon dysfunction. Note the flatfoot deformity and the forefoot abduction on the hindfoot. (B, C) Clinical views showing calcaneal valgus and forefoot abduction on a patient who suffers from posterior tibial tendon dysfunction. (D) Preoperative lateral projection showing a decrease in the calcaneal pitch, increase in the talar declination, and significant midfoot arthrosis. (E, F) Postoperative lateral and AP projections following an endoscopic gastrocnemius recession, a percutaneous calcaneal displacement osteotomy, an Evans calcaneal osteotomy, and a midfoot fusion. Note that a flexor digitorum longus tendon transfer was not performed; note also the positive changes in the calcaneal pitch angle, the talar declination, and Kite angle. The essential joints are free and function well, whereas the nonessential joints are fused in the midfoot.

By addressing the structural abnormality at the apex of the deformity, the stress on the posterior tibial tendon was significantly improved. It has been proved in cadaveric studies that realigning the hindfoot can decrease the elongating strain on the posterior tibial tendon by 51%.<sup>35</sup> The load applied on the foot is redirected as the medial

longitudinal arch is stabilized, while preserving essential motion at the hindfoot. By positioning the heel in rectus alignment with the leg, the abnormal pull of the tendoachilles and mechanical advantage of the peroneus brevis is eliminated. Another important advantage of avoiding the flexor digitorum longus tendon transfer is the decreased duration of surgery in addition to decreasing the postoperative morbidity of the soft-tissue dissection. During the postoperative period of non-weight bearing and immobilization, the posterior tibial tendon can remodel. This decision is both patient and surgeon friendly for the following reasons:

1. Less operating time
2. Fewer incision sites
3. Reduction of postoperative edema

Ultimately, the use of flexor digitorum longus tendon transfers for posterior tibial tendon augmentation in flatfoot deformity correction has been well documented in the foot and ankle literature; however, the exact role of these transfers in the overall deformity correction still remains an area of debate. There is no proof that structural support can be predictably reproduced with these tendon transfers alone. The authors offer a different perspective, and advocate bony reconstruction of the deformity to establish a biomechanically stable and functional foot and ankle. Rather than performing the tendon transfer, the authors choose to offload the posterior tibial tendon by creating a plantigrade, balanced foot and ankle. As these patients return to full activity and weight bearing, the foot and ankle is mechanically balanced. This balance removes the stress that caused the initial symptoms by neutralizing and realigning the heel under the tibia, placing the midfoot and forefoot in alignment with the hindfoot and relieving the equinus stress of the gastrocnemius and/or soleus. Physical therapy also plays a substantial role in the recovery from this surgery postoperatively.

The authors believe that with an anatomic approach to stage II posterior tibial tendon dysfunction, the need for tendon transfers or major hindfoot fusions is negated, saving operating time for the surgeon and recovery time for the patient.

## REFERENCES

1. Key JA. Partial rupture of the tendon of the posterior tibial muscle. *J Bone Joint Surg Am* 1953;35A(4):1006–8.
2. Hadfield MH, Snyder JW, Liacouras PC, et al. Effects of medializing calcaneal osteotomy on Achilles tendon lengthening and plantar foot pressures. *Foot Ankle Int* 2003;24(7):523–9.
3. Hiller L, Pinney SJ. Surgical treatment of acquired flatfoot deformity: what is the state of practice among academic foot and ankle surgeons in 2002? *Foot Ankle Int* 2003;24(9):701–5.
4. Kelikian AS. Sarrafian's anatomy of the foot and ankle. Chapter 5. 3rd edition. Philadelphia: Lippincott Williams and Wilkins; 2011.
5. Brushøj C, Henriksen BM, Albrecht-Beste E, et al. Reproducibility of ultrasound and magnetic resonance imaging measurements of tendon size. *Acta Radiol* 2006;47(9):954–9.
6. Mickle KJ, Nester CJ, Crofts G, et al. Reliability of ultrasound to measure morphology of the toe flexor muscles. *J Foot Ankle Res* 2013;6:12.
7. Otis JC, Gage T. Function of the posterior tibial tendon muscle. *Foot Ankle Clin* 2001;6(1):1–14.
8. Bare AA, Haddad SL. Tenosynovitis of the posterior tibial tendon. *Foot Ankle Clin* 2001;6(1):37–66.

9. Deland JT, deAsla RJ, Sung IH, et al. Posterior tibial tendon insufficiency: which ligaments are involved? *Foot Ankle Int* 2005;26(6):427–35.
10. Johnson KA, Strom DE. Tibialis posterior tendon dysfunction. *Clin Orthop Relat Res* 1989;(239):197–206.
11. Myerson MS, Bluman EM. Stage IV posterior tibial tendon rupture. *Foot Ankle Clin* 2007;12(2):341–62.
12. Conti S, Michelson J, Jahss M. Clinical significance of magnetic resonance imaging in preoperative planning for reconstruction of posterior tibial tendon ruptures. *Foot Ankle Int* 1992;13:208–14.
13. Funk DA, Cass JR, Johnson KA. Acquired adult flat foot secondary to posterior tibial-tendon pathology. *J Bone Joint Surg Am* 1986;68(1):95–102.
14. Jahss MH. Tendon disorders of the foot and ankle. In: Jahss MH, editor. *Disorders of the foot and ankle. Medical and surgical management*. Philadelphia: W. B. Saunders; 1991. p. 1461–513.
15. Ouzounian TJ. Late flexor digitorum longus tendon rupture after transfer for posterior tibial tendon insufficiency: a case report. *Foot Ankle Int* 1995;16:519–21.
16. Pomeroy GC, Pike RH, Beals TC, et al. Acquired flatfoot in adults due to dysfunction of the posterior tibial tendon. *J Bone Joint Surg Am* 1999;81:1173–82.
17. Otis JC, Deland JT, Kenneally S, et al. Medial arch strain after medial displacement calcaneal osteotomy: an in vitro study. *Foot Ankle Int* 1999;20:222–6.
18. Brodsky JW. Preliminary gait analysis results after posterior tibial tendon reconstruction: a prospective study. *Foot Ankle Int* 2004;25:96–100.
19. Myerson MS. Adult acquired flatfoot deformity: treatment of dysfunction of the posterior tibial tendon. *J Bone Joint Surg Am* 1996;78:780–92.
20. Fayzi AH, Nguyen HV, Juliano PJ. Intermediate term follow-up of calcaneal osteotomy and flexor digitorum longus transfer for treatment of posterior tibial tendon dysfunction. *Foot Ankle Int* 2002;23:1107–11.
21. Wacker JT, Hennessy MS, Saxby TS. Calcaneal osteotomy and transfer of the tendon of the flexor digitorum longus for stage II dysfunction of tibialis posterior: three to five year results. *J Bone Joint Surg Br* 2002;84(1):54–8.
22. Guyton GP, Jeng C, Krieger LE, et al. Flexor digitorum longus transfer and medial displacement calcaneal osteotomy for posterior tibial tendon dysfunction: a middle term clinical follow-up. *Foot Ankle Int* 2001;22:627–32.
23. Sammarco GJ, Hockenbury RT. Treatment of stage II posterior tibial tendon dysfunction with flexor hallucis longus transfer and medial displacement calcaneal osteotomy. *Foot Ankle Int* 2001;22:305–12.
24. Evans D. Calcaneo-valgus deformity. *J Bone Joint Surg Br* 1975;57:270–8.
25. Hinterman B, Valderrabano V, Kundert HP. Lengthening of the lateral column and reconstruction of the medial soft tissue for treatment of acquired flatfoot deformity associated with insufficiency of the posterior tibial tendon. *Foot Ankle Int* 1999;20:622–9.
26. Toolan BC, Sangeorzan BJ, Hansen ST. Complex reconstruction for treatment of dorsolateral peritalar subluxation of the foot. Early results after distraction arthrodesis of the calcaneocuboid joint in conjunction with stabilization of and transfer of the flexor digitorum longus tendon, to the midfoot to treat acquired pes planovalgus in adults. *J Bone Joint Surg Am* 1999;81:1545–60.
27. Moseir-LaClair S, Pomeroy G, Manoli A. Intermediate follow-up on the double osteotomy and tendon transfer procedure for stage II posterior tibial tendon insufficiency. *Foot Ankle Int* 2001;22:283–91.
28. Pomeroy GC, Manoli A 2nd. A new operative approach for flatfoot secondary to posterior tibial tendon insufficiency: a preliminary report. *Foot Ankle Int* 1997;18(4):206–12.

29. Silfverskiöld N. Reduction of the uncrossed two-joint muscles of the leg to one-joint muscles in spastic conditions. *Acta Chir Scand* 1924;56:315.
30. DiDomenico LA, Dull JM. Percutaneous displacement calcaneal osteotomy. *J Foot Ankle Surg* 2004;43(5):336–7.
31. DiDomenico L, Haro A, Cross D. Double calcaneal osteotomy using single, dual-function screw fixation technique. *J Foot Ankle Surg* 2011;50:1–3.
32. DiDomenico LA, Sann P. Univalve split plaster cast for postoperative immobilization in foot and ankle surgery. *J Foot Ankle Surg* 2013;52(2):260–2.
33. DiDomenico LA, Stein DY, Wargo-Dorsey M. Treatment of posterior tibial tendon dysfunction without flexor digitorum tendon transfer: a retrospective study of 34 patients. *J Foot Ankle Surg* 2011;50:293–8.
34. Valderrabano V, Hintermann B, Wischer T, et al. Recovery of the posterior tibial muscle after late reconstruction following tendon rupture. *Foot Ankle Int* 2004;25(2):85–95.
35. Graham ME, Jawrani NT, Goel VK. Effect of extra-osseous talotarsal stabilization on posterior tibial tendon strain in hyperpronating feet. *J Foot Ankle Surg* 2011;50:676–81.